



PATIENT

Alphie McChesney

SPECIES

Feline

BREED

DSH

SEX

Male Neutered

AGE

9 years

WEIGHT

12lbs

INTERPRETED BY

Maggie Machen Lamy,
 DVM DACVIM
 (Cardiology)

IMAGING PERFORMED BY

Kelly Reschny, RVT

HOSPITAL NAME

Prince Charles Animal
 Hospital

REFERRING VET

Dr. Momi

INVOICE

46574

DATE

1/26/26

PRESENTING CLINICAL SIGNS

History: Grade 2/6 heart murmur. Assess prior to dental.

ELECTROCARDIOGRAPHIC FINDINGS

A six lead ECG is available at 25mm/s; 10mm/mV. The average heart rate is 190bpm. P waves cannot be identified in lead two; however, are inverted in lead one. The QRS is inverted. The MEA is indeterminant. No ectopic beats, pauses or dysrhythmias observed. ECG diagnosis: Normal sinus rhythm.

ECHOCARDIOGRAM FINDINGS

2D, m-mode, color flow and doppler imaging is available. The left ventricular wall is largely normal in dimension. There is a mildly hyperechoic endocardium consistent with fibrosis. The papillary muscles are mildly hyperechoic. The left atrium is normal in size. The right atrium is normal in size. The right ventricle appears normal. The mitral valve is normal with mild MR. No TR. Blood flow through the RVOT is normal. The blood flow through the LVOT is mildly elevated secondary to systolic anterior motion of the mitral valve. No AI. Aortic root is normal. No pleural or pericardial effusion seen. No obvious cardiac tumors.

CARDIAC CHART

FELINE CARDIAC PARAMETERS	BODY WEIGHT (kg)	HR (BPM)	IVSd (cm) (Moise, Pipers)	LVIDd (cm) (Moise, Pipers)	LVWd (cm) (Moise, Pipers)	FS (%)	EF (%)
NORMAL PARAMETER	-----	150-240	0.35-0.55	<2 (mean 1.5)	3.5-0.55	35-67	80-100
PATIENT	5.4	140	0.48	1.6	0.47	57	92
FELINE CARDIAC PARAMETERS	LA/AO (Boon)	LA/AO HEART BASE (Swe) (Abbott)	LA 2D short axis Base view (cm) (Abbott)		LVOT VEL (m/s)	RVOT VEL (m/s)	E max (m/s)
NORMAL	<1.5	<1.3	<1.2		<1.6	<1.3	<0.9
PATIENT	1.2	1.3	1.1		1.4	1.5	NM

*Note: All measurements based upon multi-modal images and methods. An average value is reported.
 Adapted from June Boon, Veterinary Echocardiography, 1998
 Abbott J & MacLean H JVIM 2006;20: 111-119, Moise et al. Am J Vet Res 47:1476, 1986. Pipers et al. Am J Vet Res 40:882, 1979.

INTERPRETATION OF THE FINDINGS & FURTHER RECOMMENDATIONS

The cause of the murmur is an LVOT obstruction with mild secondary MR. The LV is largely normal with no evidence of significant hypertrophy and monitoring is advised. These findings may suggest early HOCM; however, a normal stress-related variant cannot be ruled out. The LA is normal, and no additional issues are identified. The ECG is largely normal, with a sinus rhythm.

Given these findings, no medications are indicated. Should the degree of hypertrophy worsen, Atenolol may be recommended in the future.

Prognosis is guarded.



PATIENT

Alphie McChesney

Anesthetic risk is considered mild. Additionally, steroids should be used with caution in general, as even a 'normal' heart can develop evidence of intolerance and fluid retention.

SPECIES

Feline

Monitor for any development of clinical signs, including labored breathing or signs of a blood clot (paralysis, neurologic change). Prognosis is guarded prior to assessing for progression.

BREED

DSH

A recheck echocardiogram is recommended in 6-12 months to screen for any evidence of progression.

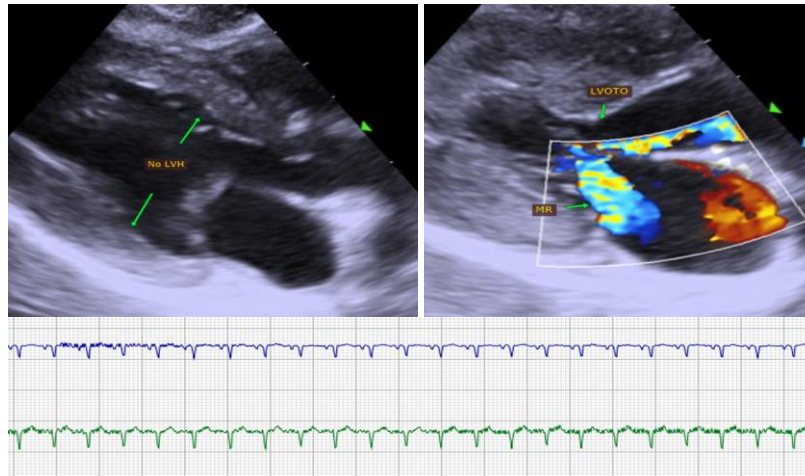
SEX

Male Neutered

AGE

9 years

IMAGES



WEIGHT

12lbs

INTERPRETED BY

Maggie Machen Lamy,
 DVM DACVIM
 (Cardiology)

The information and recommendations provided are based on the images presented by the referring veterinarian. No evaluation can be communicated regarding pathology that was not visible in the image/video clips provided.

IMAGING PERFORMED BY

Kelly Reschny, RVT

Thank you for this referral. This report was generated using transcription software, and minor dictation errors may be present. If the clinical or image interpretation does not parallel your findings or if I can be of any further assistance, please contact me.

HOSPITAL NAME

Prince Charles Animal
 Hospital

Maggie Machen Lamy, DVM
 Diplomate of the American College of Veterinary Internal Medicine (Cardiology)
 info@sonopath.com

REFERRING VET

Dr. Momi

INVOICE

46574

DATE

1/26/26



PATIENT

Alphie McChesney

SPECIES

Feline

BREED

DSH

SEX

Male Neutered

AGE

9 years

WEIGHT

12lbs

INTERPRETED BY

Maggie Machen Lamy,
DVM DACVIM
(Cardiology)

**IMAGING
PERFORMED BY**

Kelly Reschny, RVT

HOSPITAL NAME

Prince Charles Animal
Hospital

REFERRING VET

Dr. Momi

INVOICE

46574

DATE

1/26/26